

PediatricsⁱⁿReview[®]

Periorbital and Orbital Cellulitis
Andrea Hauser and Simone Fogarasi
Pediatr. Rev. 2010;31;242-249
DOI: 10.1542/pir.31-6-242

The online version of this article, along with updated information and services, is located on the World Wide Web at:

<http://pedsinreview.aappublications.org/cgi/content/full/31/6/242>

Pediatrics in Review is the official journal of the American Academy of Pediatrics. A monthly publication, it has been published continuously since 1979. Pediatrics in Review is owned, published, and trademarked by the American Academy of Pediatrics, 141 Northwest Point Boulevard, Elk Grove Village, Illinois, 60007. Copyright © 2010 by the American Academy of Pediatrics. All rights reserved. Print ISSN: 0191-9601. Online ISSN: 1526-3347.

American Academy of Pediatrics

DEDICATED TO THE HEALTH OF ALL CHILDREN™



Periorbital and Orbital Cellulitis

Andrea Hauser, MD,*
Simone Fogarasi, MD†

Author Disclosure
Drs Hauser and Fogarasi have disclosed no financial relationships relevant to this article. This commentary does not contain a discussion of an unapproved/investigative use of a commercial product/device.

Objectives After completing this article, readers should be able to:

1. Recognize the difference between periorbital and orbital cellulitis on the basis of history and physical examination findings.
2. Describe the cause, pathophysiology, and management of periorbital and orbital cellulitis.
3. Understand the importance of sinus disease in both periorbital and orbital cellulitis.
4. Know the indications for computed tomography scan and specialist consultation for eyelid swelling.
5. Recognize the complications of periorbital and orbital cellulitis.

Case Study

A 19-month-old boy presents with a 1-day history of left eyelid swelling. The swelling is greater in the lower lid and accompanied by local erythema, tenderness, and temperature up to 38.4°C. His parents state that he has decreased appetite and activity. For the past week, the boy has been experiencing clear, watery rhinorrhea, sneezing, and a mild cough. Today, he was given diphenhydramine without any improvement of the eyelid swelling. His parents deny any history of trauma or recent insect bites to the face. The past medical history is significant for mild intermittent asthma and allergic rhinitis. He is exposed to tobacco at home.

On physical examination, the child appears ill, but not toxic. His temperature is 36.9°C, heart rate is 123 beats/min, respiratory rate is 26 breaths/min, and blood pressure is 117/82 mm Hg. Both upper and lower left eyelids appear significantly edematous, with surrounding erythema and tenderness to light touch. No chemosis or proptosis is apparent. Extraocular movements and visual acuity can be evaluated only partially due to pain.

Introduction

Infections of the eye occur in the pediatric population and may present with complaints of eyelid swelling and pain. Expedient and proper diagnosis is essential because there is potential for significant morbidity and mortality. Periorbital and orbital infections have much in common. We illustrate the similarities and differences of these two clinical entities.

Anatomic Considerations

The orbital septum is a thin membrane separating the superficial eyelid from the deeper orbital structures. This septum forms a potential barrier, preventing infections of the eyelid from penetrating deeper into the orbit. Infection of the soft tissues anterior to the orbital septum is termed periorbital cellulitis and affects the eyelids and adnexa. Infections posterior to the septum include orbital cellulitis, orbital abscess, and subperiosteal abscess.

Certain anatomic characteristics of the orbital structures allow extension of infection to adjacent structures. First, the thin orbital septum may be incomplete, thereby risking the spread of periorbital infection to underlying orbital structures. Second, infection may spread from the paranasal sinuses (which surround the orbital cavity on three of the orbit's four walls) through the bone into the orbit. Third, the valveless orbital

Abbreviations

CNS:	central nervous system
CT:	computed tomography
Hib:	<i>Haemophilus influenzae</i> type b
MRSA:	methicillin-resistant <i>Staphylococcus aureus</i>
RPOC:	recurrent periorbital cellulitis

*Pediatric Hospitalist, New Orleans Children's Hospital, New Orleans, La.

†Pediatric Hospitalist, Ochsner Medical Center, New Orleans, La.

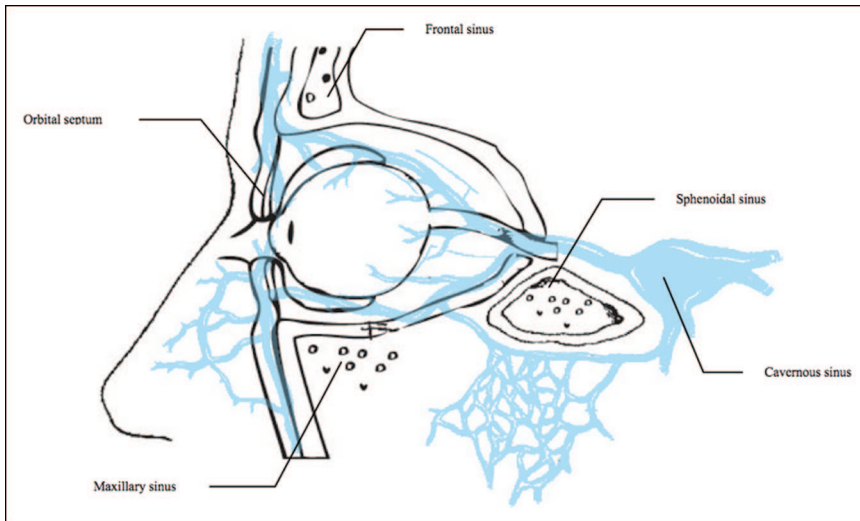


Figure 1. Simplified anatomy of the eye, paranasal sinuses, and venous drainage.

veins can allow passage of hematogenous infection in both antegrade and retrograde directions (Fig. 1).

Epidemiology

Periorbital cellulitis is a bacterial infection of the eyelid and surrounding soft tissues. It is primarily a pediatric disease, occurring mostly in patients younger than 5 years of age, and is almost three times more common than orbital cellulitis. There is no sex predilection.

Orbital bacterial infections can present in all age groups but are seen more often in the pediatric population. In a retrospective analysis of pediatric orbital infections, the average age of affected patients was 6.8 years, ranging from 1 week to 16 years. (1) A 2:1 male predominance has been described. Throughout the world, orbital cellulitis occurs more often in winter months because it is associated closely with paranasal sinus and upper respiratory tract infections. Most cases have a unilateral presentation. (2)(3)

Pathogenesis

Rhinosinusitis, especially ethmoiditis, is by far the most common predisposing factor for pediatric orbital cellulitis. However, periorbital and orbital cellulitis also can result from extension of external ocular infection such as a hordeolum (stye) or dacryocystitis/dacryoadenitis (infection of the lacrimal system); an upper respiratory tract infection, such as complicated rhinosinusitis (Fig. 2); a dental abscess (Fig. 3); a superficial break in the skin, due either to an infected insect bite, impetigo, acne, eczema, periocular surgery, or direct penetrating injury to the orbit; and hematogenous seeding.

Microbiology

Haemophilus influenzae type b (Hib) historically was one of the pathogens associated most commonly with orbital cellulitis and hematogenously spread periorbital cellulitis. With the advent of the Hib conjugate vaccine in 1985, the incidence of Hib infections has declined significantly. However, Hib still should be considered, particularly in unimmunized or partially immunized children, because invasive Hib disease in children younger than 5 years of age has been reported recently. (4) *Streptococcus pneumoniae* infections also are on the decline as a result of the routine use of pneumococcal conjugate

vaccine. Consequently, the pattern of pathogens responsible for eye infections is evolving.

Currently, *Staphylococcus aureus*, *S epidermidis*, and *S pyogenes* account for approximately 75% of pediatric periorbital infections from which cultures are obtained. (5) *Staphylococcus* and *Streptococcus* have become the two most common pathogens responsible for pediatric orbital cellulitis. Community-acquired methicillin-resistant *S aureus* (MRSA) has become increasingly prevalent (Fig. 4). (6) In fact, one retrospective study from Houston, Texas, examining the microbiology of pediatric orbital cellulitis, found that MRSA represented 73% of all *S aureus* isolates. (1)

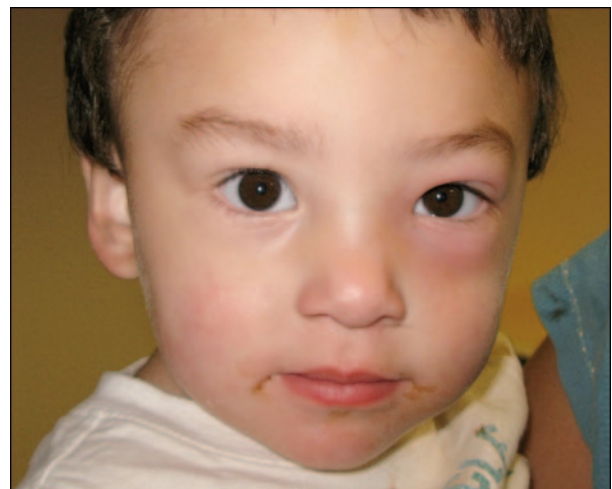

Figure 2. A 19-month-old boy who has periorbital cellulitis and presents with left eyelid swelling, erythema, and tenderness due to acute rhinosinusitis.

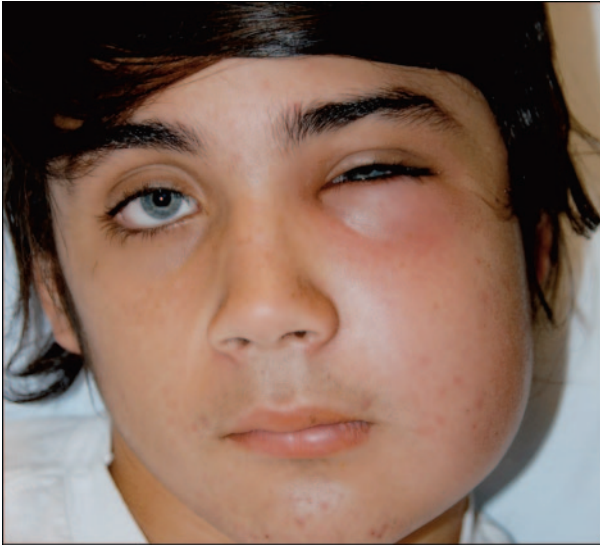

Figure 3. A 14-year-old boy who presented with marked left-sided facial pain. Prior to admission, he developed facial swelling that progressed to involve the left eyelid. He was diagnosed with left periorbital cellulitis and a tooth abscess, prompting intravenous clindamycin therapy and tooth extraction.

Other, less common organisms found in pediatric orbital abscess fluid and sinus cultures include *S milleri*, *Haemophilus*, *Neisseria*, diphtheroids, *Bacteroides*, *Veillonella*, *Prevotella*, *Peptostreptococcus*, and *Moraxella catarrhalis*. (1) Polymicrobial infections involving aerobic and anaerobic bacteria also have been described in odontogenic disease.

Clinical Aspects

Unilateral erythema, swelling, warmth, and tenderness of the eyelid can be seen in both periorbital and orbital cellulitis. Fever, systemic signs, and a significant degree of toxicity may be present. Blurred vision, ophthalmoplegia, proptosis, and chemosis help identify orbital cellulitis because they are signs of increased intraorbital pressure, which should not be present in periorbital cellulitis (Fig. 5).

Hematogenous spread with periorbital seeding should be considered in children younger than age 3 years who present with systemic signs of illness and rapidly progressive eyelid swelling preceded by a viral upper respiratory tract infection.

When evaluating a child for possible periorbital or orbital cellulitis, a history of past sinus or dental disease, previous eye surgery, and trauma should be explored. It can be challenging to assess the eye. The clinician should begin the examination with the least invasive maneuvers. If there is a large amount of swelling around the eye, it

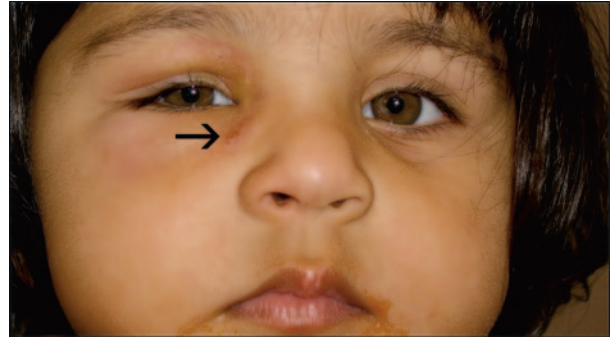

Figure 4. A 15-month-old girl who has periorbital cellulitis and fever following infection of an insect bite to her lower right eyelid despite treatment with several days of cephalexin. She was placed on clindamycin for suspected community-acquired methicillin-resistant *Staphylococcus aureus* infection and improved over the next 48 hours.

may be necessary to retract the eyelids. If complete examination of the affected eye is not possible, imaging and consultation with an ophthalmologist may be appropriate.

Infection must be differentiated from other causes of eyelid swelling, such as allergic reactions (which usually respond to antihistamine medications), edema due to hypoproteinemia (classically presenting with bilateral eyelid edema and other associated signs of fluid reten-

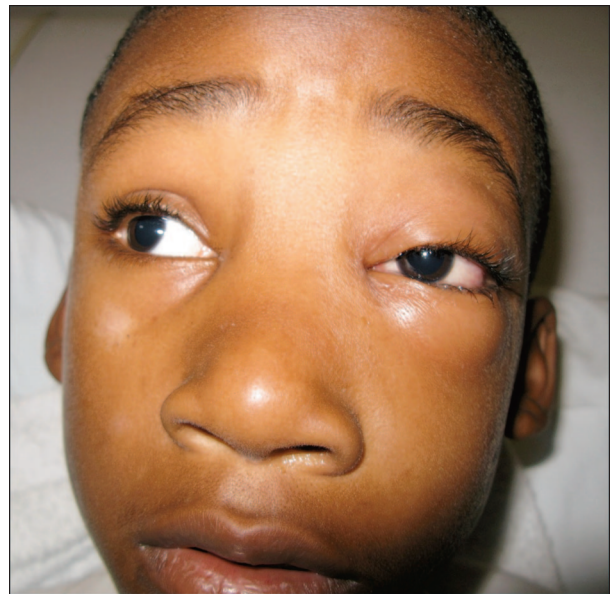

Figure 5. An 11-year-old boy who has pan-sinusitis and left orbital cellulitis and presented with fever, severe left eye pain, proptosis, chemosis, and limitation of extraocular movements. Note that he has limited adduction of his left eye.

tion), and rarely, orbital wall infarction and subperiosteal hematomas in patients who have sickle cell disease. (7)

Several other clinical entities belong in the differential diagnosis of proptosis. One is idiopathic inflammation from orbital pseudotumor, which can present with pain, proptosis, local swelling, and conjunctival injection. Patients who have orbital pseudotumor also may have diplopia, visual loss, ptosis, and limited extraocular movements. Radiographic findings demonstrate inflammatory changes and an abnormal mass density of the intraorbital soft tissues. Computed tomography (CT) scan is essential for differentiating orbital pseudotumor from orbital cellulitis because pseudotumor requires corticosteroid administration for treatment. (8) Other disorders that present with proptosis include orbital myositis, Wegener granulomatosis, sarcoidosis, leukemia, Burkitt lymphoma, rhabdomyosarcoma, retinoblastoma, metastatic carcinoma, and histiocytosis. Dysthyroid exophthalmos as a result of endocrine dysfunction also can present with proptosis.

Periorbital cellulitis is diagnosed primarily on clinical findings and does not require routine laboratory or radiologic confirmation, unless the diagnosis is unclear or neurologic involvement is a concern. Wound culture of a purulent drainage site may be helpful if a resistant or unusual pathogen is suspected as well as blood cultures if systemic symptoms are present and hematogenous spread is suspected.

Management

Management of simple periorbital cellulitis usually is empiric and should offer coverage of *Staphylococcus* and *Streptococcus* (Table). Knowledge of local prevalence and characteristics of MRSA should determine the choice of first-line therapy for this organism. No evidence suggests that intravenous antibiotics are better than oral antibiotics in the management of simple periorbital cellulitis (10) in terms of quicker recovery time or prevention of secondary complications. Therefore, the choice of route should be based on general appearance of the patient, ability to take oral medication, compliance, and clinical progression of the disease. The typical length of therapy is 7 to 10 days but ultimately should be guided by symptom resolution. Clinical improvement should be evident within 24 to 48 hours. If expected improvement does not occur, complications or resistant organisms may be present, and consultation with an infectious disease specialist, ophthalmologist, otolaryngologist, and neurosurgeon should be considered. (11)

Periorbital cellulitis as a consequence of hematogenous seeding requires inpatient management with paren-

teral antimicrobial coverage of both gram-positive and gram-negative organisms. Transition to oral antibiotics may be considered once significant improvement has been achieved, for a total 10- to 14-day course. A full septic evaluation must be considered if the patient appears toxic or evidence suggests neurologic involvement.

A high white blood cell count, C-reactive protein value, or erythrocyte sedimentation rate may suggest the diagnosis of orbital cellulitis over the more superficial periorbital cellulitis. However, these studies alone never should be used to make a definitive diagnosis.

The clinician should try to obtain cultures for identification and sensitivity of the pathogens involved. Although blood cultures are obtained to evaluate for bacteremia, a retrospective study from Texas Children's Hospital had only a 7% yield for a positive blood culture in pediatric orbital cellulitis infections associated with sinus disease. Due to the low yield, routine blood cultures are not indicated for patients who lack evidence of bacteremia or systemic illness. Culture of other sites was found to be more successful in identifying an organism. Ocular discharge can be cultured with high yield. Orbital, epidural abscess, and sinus fluid obtained surgically may be positive in more than 90% of cases. (1) Less invasive culture techniques may be helpful, including swabbing of the maxillary or ethmoid sinus aperture, just beneath the turbinates.

Patients who have orbital cellulitis presenting with eyelid swelling, diplopia, reduced visual acuity, abnormal light reflexes, proptosis, or ophthalmoplegia should be admitted for inpatient care. In addition, any patient who appears systemically ill or presents with signs of central nervous system (CNS) involvement such as lethargy, vomiting, headache, seizure, or cranial nerve deficit should be admitted. Finally, any patient for whom it is not possible to examine the eye fully should be monitored as an inpatient.

Ideally, an interdisciplinary team comprised of a pediatric ophthalmologist, pediatric otorhinolaryngologist, and pediatrician should provide inpatient care to patients requiring admission. Medical management with intravenous antibiotics most often is sufficient treatment. Antibiotic therapy should have empiric coverage against staphylococcal and streptococcal species as well as organisms associated with rhinosinusitis. MRSA coverage should be strongly considered. Clindamycin plus a second- or third-generation cephalosporin is a reasonable initial regimen. Orbital cellulitis requires antibiotic therapy for a total of 10 to 14 days. Transitioning from parenteral to oral antibiotics may be considered once significant improvement has been achieved.

Table. Management of Periorbital Cellulitis

Predisposing Factor	Pathogen	Management	Other Considerations
Hordeolum (stye)	<i>Staphylococcus aureus</i>	Oral dicloxacillin, first-generation cephalosporin Oral trimethoprim-sulfamethoxazole (TMP-SMX) or clindamycin if methicillin-resistant <i>S aureus</i> (MRSA) is suspected	Warm compresses may hasten drainage
Dacryoadenitis, dacryocystitis	<i>Streptococcus pneumoniae</i> <i>S aureus</i> <i>S pyogenes</i> <i>Haemophilus influenzae</i> <i>Pseudomonas aeruginosa</i>	Empiric therapy based on Gram stain of aspirate	Consider ophthalmologic consultation
Insect bite	<i>S aureus</i>	Oral dicloxacillin, first-generation cephalosporin	
Impetigo	<i>S pyogenes</i>	Oral TMP-SMX or clindamycin if MRSA is suspected	
Eczema		Vancomycin for severe infections	
Complicated rhinosinusitis	<i>S pneumoniae</i> <i>H influenzae</i> <i>Moraxella catarrhalis</i>	High-dose amoxicillin-clavulanate, oral second- or third-generation cephalosporin (cefuroxime, cefdinir, or cefpodoxime) for 10 to 14 days If clinical improvement is not achieved, consider intravenous cefotaxime or ceftriaxone	Consider otolaryngologist consultation
Dental abscess	Mixed aerobic and anaerobic bacteria	Clindamycin or amoxicillin-clavulanate/ampicillin-sulbactam	Evaluation by a dentist is suggested
Hematogenous spread associated with preceding viral upper respiratory tract infection	<i>S pneumoniae</i> <i>H influenzae</i> <i>S pyogenes</i> <i>S aureus</i>	Parenteral third-generation cephalosporin (cefotaxime or ceftriaxone) plus clindamycin or vancomycin if MRSA is suspected	

From Custer et al. (9)
Dose suggestions follow; confirm all doses prior to use.
Amoxicillin/clavulanate: 80 to 90 mg/kg per day PO divided every 8 to 12 hours
Ampicillin/sulbactam: 100 to 200 mg/kg per day IV divided every 6 hours (based on ampicillin component)
Cefotaxime: 100 to 200 mg/kg per day IV divided every 6 to 8 hours
Ceftriaxone: 50 to 100 mg/kg per day IV divided every 12 to 24 hours
Clindamycin: 10 to 30 mg/kg per day PO divided every 6 to 8 hours, 25 to 40 mg/kg per day IV every 6 to 8 hours
Dicloxacillin: Mild/moderate infection, 12.5 to 25 mg/kg per day PO divided by every 6 hours; severe infection, 50 to 100 mg/kg per day PO divided every 6 hours
TMP/SMX: Mild/moderate infection, 8 to 12 mg/kg per day divided every 12 hours; severe infection, 20 mg/kg per day divided every 6 to 8 hours
Vancomycin: 40 mg/kg per day divided every 6 to 8 hours

Adjuvant therapies for rhinosinusitis, such as saline nasal irrigation, antihistamines, decongestants, mucolytic agents, and intranasal steroids, currently are not recommended. (11) One small retrospective study (12) reported that intravenous corticosteroids do not appear to affect clinical outcomes adversely and may be beneficial in the treatment of pediatric orbital cellulitis with subperiosteal abscesses. However, corticosteroid therapy may depress the patient's immune response and allow or mask the progression of infection. Future prospective, randomized research is needed to clarify the role of corticosteroids in treating orbital infections.

Contrast-enhanced CT scanning with sagittal, coronal, and axial slices of the orbit and sinuses is the ideal modality for localizing sinus infection and staging the extent of orbital inflammation (Fig. 6). Indications for CT scan include: 1) eyelid edema that makes complete examination impossible; 2) presence of CNS involvement (such as focal neurologic deficits, seizure, or altered mental status); 3) deteriorating visual acuity or color vision, gross proptosis, or ophthalmoplegia; and 4) clinical deterioration or no improvement after 24 to 48 hours of appropriate treatment. Baseline CT scan should not be performed routinely due to radiation exposure. (3)

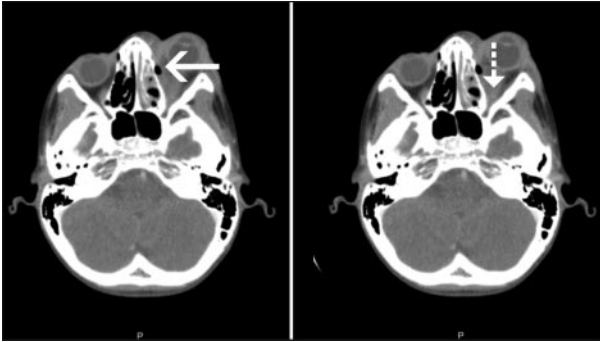


Figure 6. Contrast-enhanced computed tomography scan for a patient who has orbital cellulitis. The sagittal image shows marked left proptosis, intraorbital free air (solid arrow), phlegmon formation, and left paranasal sinus opacification. The coronal view demonstrates stranding of the intraconal fat along the orbital floor (dotted arrow).

On CT scan, several changes may be evident in orbital cellulitis, including diffuse fat infiltration, subperiosteal abscess, and true orbital abscesses. Foreign bodies may be detected, depending on the characteristics of the foreign body.

The primary goals of surgical intervention include draining abscesses, releasing pressure on the orbit, and obtaining cultures to guide antimicrobial therapy. Surgical consultants should determine whether surgery is indicated. Possible surgical interventions for orbital cellulitis include sinus surgery, canthotomy, orbital surgery, combined sinus and orbital surgery, and neurosurgery.

Complications and Prognosis

Complications of periorbital cellulitis include local abscess formation, ensuing orbital cellulitis, and intracranial extension of infection.

Recurrent periorbital cellulitis (RPOC) is a clinical condition described as three periorbital infections occurring within 1 year, spaced by at least 1 month of convalescence. This entity should be distinguished from treatment failure due to microbial resistance. The most common causes of RPOC are comparable to those of acute periorbital infection. Other underlying causes must be considered, including atopy, nonbacterial organisms such as herpes simplex (Fig. 7) and atypical mycobacteria, collagen vascular disorders, systemic diseases (such as human immunodeficiency virus infection), intraorbital or paranasal neoplasms, and structural/anatomical abnormalities (osteomeatal obstruction, abnormal uncinat process). A thorough clinical reassessment and, in some cases, imaging may help elicit the fundamental cause. (13)(14)

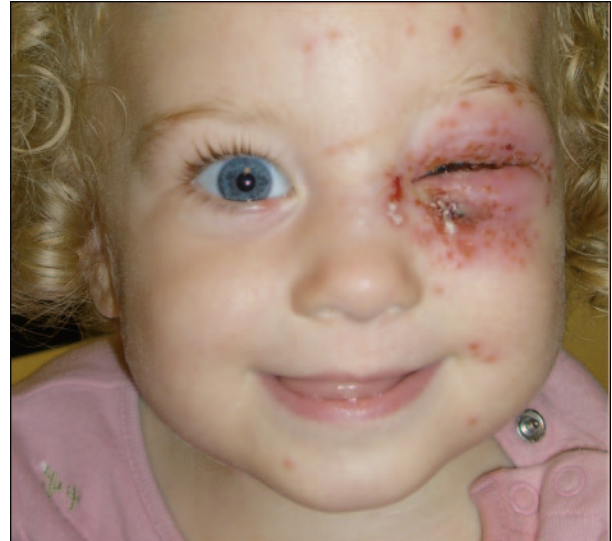

Figure 7. A 15-month-old girl who has recurrent periorbital cellulitis and was diagnosed with herpes simplex virus-1 via direct fluorescent assay. She was treated with acyclovir.

Although the incidence of orbital cellulitis is low, serious complications are likely if the infection is not treated. Cavernous sinus thrombosis is one such untoward complication. This condition may be challenging to diagnose because it may present similarly to orbital cellulitis or may occur as a consequence of it. Typically, patients who have cavernous sinus thrombosis have acute or slowly progressive proptosis, periorbital edema, and ophthalmoplegia. Loss of vision and meningismus may be late findings.

Both orbital cellulitis and cavernous sinus venous thrombosis can extend and progress to intracranial infections, such as subdural empyema, intracerebral abscess, extradural abscess, and meningitis. These severe complications are associated with high morbidity and sometimes with mortality. Septic emboli of the optic nerve as well as ischemia due to compression may cause visual loss. Magnetic resonance imaging may be of value in determining these circumstances.

Case Study Follow-up

Laboratory tests showed a white blood cell count of $15.86 \times 10^3/\text{mcL}$ ($15.86 \times 10^9/\text{L}$) (59% neutrophils, 1% bands, 28% lymphocytes, 12% monocytes), a hemoglobin concentration of 13.3 g/dL (133 g/L), and a platelet count of $497 \times 10^3/\text{mcL}$ ($497 \times 10^9/\text{L}$). A CT scan of the orbits was obtained due to the inability to examine the eye fully. Imaging revealed extensive left periorbital soft-tissue swell-

ing, with extension of edema or a phlegmon noted between the medial rectus muscle and adjacent lamina papyracea. Complete opacification of both maxillary and ethmoid sinuses was noted.

The patient was admitted to the hospital with ophthalmology and otorhinolaryngology consultation and placed on intravenous ceftriaxone and clindamycin therapy and pain control. After 3 days of hospitalization, he showed significant improvement, with decreased eyelid swelling and resolution of pain. He was switched to oral antibiotic therapy and discharged from the hospital with follow-up appointments with his pediatrician, ophthalmologist, and otorhinolaryngologist.

Summary

- Eyelid swelling is a common pediatric complaint and must be evaluated expeditiously by a pediatrician.
- Based primarily on consensus and observational studies, differentiation of periorbital and orbital cellulitis must be attempted through thorough history taking, including predisposing factors, and physical examination focused on the eye. (5)
- CT scan scanning may aid in the diagnosis, according to primarily consensus and observational studies. (3)
- Based primarily on consensus and observational studies, simple periorbital cellulitis may be treated empirically with oral antibiotic therapy and close follow-up. (10)
- Consensus and observational studies suggest that early recognition and treatment of orbital cellulitis is essential. (2)
- When a patient presents with ophthalmoplegia and proptosis, consensus and observational studies recommend initiation of appropriate empiric antibiotic therapy targeted at MRSA and *Streptococcus*. (6)
- Based primarily on consensus and observational studies, the patient's clinical course must be monitored closely, with clinical deterioration or lack of improvement possibly requiring imaging to look for underlying complications and determine the need for surgical intervention.

ACKNOWLEDGMENTS. Special acknowledgments to Dr Tere Vives, Dr Pulin Shah, Alonso Sierra, and Ximena San Vicente for their invaluable assistance.

References

1. McKinley SH, Yen MT, Miller AM, et al. Microbiology of pediatric orbital cellulitis. *Am J Ophthalmol*. 2007;144:497–501
2. Liu IT, Kao SC, Wang AG, Tsai CC, Liang CK, Hsu WM. Preseptal and orbital cellulitis: a 10-year review of hospitalized patients. *J Chin Med Assoc*. 2006;69:415–422
3. Ho CF, Huang YC, Wang CJ, Chiu CH, Lin TY. Clinical analysis of computed tomography-staged orbital cellulitis in children. *J Microbiol Immunol Infect*. 2007;40:518–524
4. Centers for Disease Control and Prevention. Invasive *Haemophilus influenzae* type B disease in five young children—Minnesota, 2008. *MMWR Morbid Mortal Wkly Rep*. 2009;58:1–3
5. Botting AM, McIntosh D, Mahadevan M. Paediatric pre- and post-septal peri-orbital infections are different diseases. A retrospective review of 262 cases. *Int J Pediatr Otorhinolaryngol*. 2008;72:377–383
6. Blomquist PH. Methicillin-resistant *Staphylococcus aureus* infections of the eye and orbit. *Trans Am Ophthalmol Soc*. 2006;104:322–345
7. Ozkavukcu E, Fitoz S, Yagmurlu B, Ciftci E, Erden I, Ertem M. Orbital wall infarction mimicking periorbital cellulitis in a patient with sickle cell disease. *Pediatr Radiol*. 2007;37:388–390
8. Anderson J, Thomas T. Orbital pseudotumor presenting as orbital cellulitis. *Can J Emerg Med*. 2006;8:123–125
9. Custer JW, Rau RE, Lee CK, eds. *The Harriet Lane Handbook: a Manual for Pediatric House Officers/the Harriet Lane Service, Children's Medical and Surgical Center of the Johns Hopkins Hospital*. 18th ed. Philadelphia, Pa: Mosby; 2008
10. Al-Nammari S, Robertson B, Ferguson C. Should a child with preseptal periorbital cellulitis be treated with intravenous or oral antibiotics? *Emerg Med J*. 2007;24:128–129
11. American Academy of Pediatrics. Clinical practice guideline: management of sinusitis. *Pediatrics*. 2001;108:798–808
12. Yen MT, Yen KG. Effect of corticosteroids in the acute management of pediatric orbital cellulitis with subperiosteal abscess. *Ophthalmic Plast Reconstruct Surg*. 2005;21:363–367
13. Sorin A, April MM, Ward RF. Recurrent periorbital cellulitis: an unusual clinical entity. *Otolaryngol Head Neck Surg*. 2006;134:153–156
14. Karkos PD, Karagama Y, Karkanavatos A, Srinivsan V. Recurrent periorbital cellulitis in a child: a random event or an underlying anatomical abnormality? *Int J Pediatr Otorhinolaryngol*. 2004;68:1529–1532

PIR Quiz

Quiz also available online at <http://www.pedsinreview.aappublications.org>

11. A 3-year-old unimmunized child presents with a 1-day history of acute left eyelid swelling. She also has had mild rhinorrhea and nasal congestion for the past 3 days. She never has been hospitalized with any serious illness. Of note, her father intermittently complains of skin boils, which usually resolve without treatment. Physical examination of the nontoxic-appearing child reveals swollen, erythematous, indurated eyelids of the left eye and mild nasal discharge. Of the following, the MOST appropriate management plan is:
 - A. Anticipatory guidance only.
 - B. Antihistamine and follow-up visit if symptoms worsen.
 - C. Hospital admission for intravenous (IV) antibiotics (to cover methicillin-resistant *Staphylococcus aureus* [MRSA] and *Haemophilus influenzae* type b).
 - D. Initiation of oral antibiotics to cover MRSA and *H influenzae* type b.
 - E. Ophthalmology consultation and computed tomography scan of the orbits.
12. You have been caring for a 2-year-old previously healthy boy who has been hospitalized for presumed orbital cellulitis of his right eye. After receiving IV antibiotics for 36 hours, his right eyelid swelling, eye pain, and proptosis have improved noticeably, although they have not resolved completely. In discussion with the family, your plan now includes which of the following?
 - A. Addition of a third IV antibiotic to hasten recovery.
 - B. Addition of steroids to hasten recovery while receiving antibiotics.
 - C. Consultation with a pediatric ophthalmologist for possible surgical intervention.
 - D. Continuation of both IV antibiotics until all symptoms resolve, then discharge.
 - E. Switching to comparable oral antibiotics to complete a 10- to 14-day course at home.
13. A 6-year-old child is brought to the emergency department by his parents because of upper respiratory tract symptoms, a progressively swollen left eye, and altered mental status. He has been otherwise healthy and is fully immunized. Upon examination, he is difficult to arouse. Local signs include a markedly swollen left eye with proptosis. Eye movements are difficult to assess because of the boy's poor neurologic status. He is febrile, but hemodynamically stable. The most likely pathogenesis is:
 - A. Acute bacterial meningitis, with secondary infection of the left orbit.
 - B. Bacteremia causing both ocular and intracranial illness.
 - C. Head trauma, with ocular and intracranial manifestations.
 - D. Intracranial mass causing ocular and neurologic manifestations.
 - E. Orbital cellulitis, with the neurologic complication of bacterial meningitis.
14. A father calls your office to report that his 2-year-old daughter has had nasal congestion and fever for the past 2 days. She received a nonprescription medication this morning, and today her right eye is "swollen shut." When she arrives in your office, she is febrile but nontoxic. Her right eyelids are swollen and erythematous. It is nearly impossible to determine whether her extraocular movements are normal, but she exhibits increased tearing of the affected eye. Of the following, the most reasonable diagnosis and plan of treatment are:
 - A. Allergic reaction and trial of antihistamine at home.
 - B. Periorbital cellulitis and IV antibiotics and CT scan of the orbits.
 - C. Periorbital cellulitis and ophthalmology consultation and IV antibiotics.
 - D. Periorbital cellulitis and oral antibiotics at home.
 - E. Reactive periorbital swelling from sinusitis and nasal decongestant at home.

Periorbital and Orbital Cellulitis
Andrea Hauser and Simone Fogarasi
Pediatr. Rev. 2010;31;242-249
DOI: 10.1542/pir.31-6-242

**Updated Information
& Services**

including high-resolution figures, can be found at:
<http://pedsinreview.aappublications.org/cgi/content/full/31/6/242>

Permissions & Licensing

Information about reproducing this article in parts (figures,
tables) or in its entirety can be found online at:
<http://pedsinreview.aappublications.org/misc/Permissions.shtml>

Reprints

Information about ordering reprints can be found online:
<http://pedsinreview.aappublications.org/misc/reprints.shtml>

American Academy of Pediatrics

DEDICATED TO THE HEALTH OF ALL CHILDREN™

